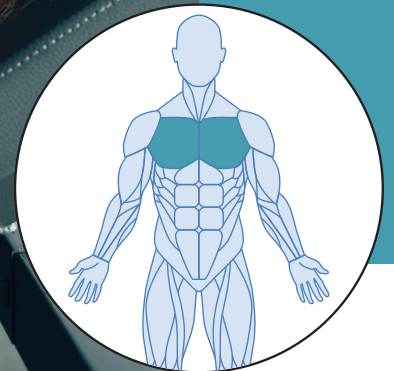


MUSCLE OF THE MONTH



CHEST

The chest forms part of a larger group of “pushing” muscles in the upper body and is made up of three muscles: pectoralis major, minor and the serratus anterior.

PECTORALIS MAJOR

This is the larger of the chest muscles and is responsible for adduction of the arms, rotation of the arm forward and when the arms are raised in a fixed position (like you are wall climbing) it works with the teres major and the latissimus dorsi to pull your torso upwards.

PECTORALIS MINOR

This muscle sits below the pectoralis major and it attaches into the scapula. It is responsible for pulling the shoulder forward and down.

SERRATUS ANTERIOR

Also known as the “boxer’s muscle”. Although it might not be a true chest muscle, it is classed in this group because of its attachment on the ribs near the pectoral muscles.